



Successful pregnancy and delivery after a vitrified-warmed embryo transfer in a woman with Kallmann syndrome : A case report and literature review

Aya Shiraiwa¹⁾, Toshifumi Takahashi²⁾, Chihiro Okoshi¹⁾, Marina Wada¹⁾, Kuniaki Ota²⁾,
Ryota Suganuma¹⁾, Masatoshi Jimbo²⁾, Shu Soeda¹⁾, Takafumi Watanabe¹⁾,
Hiromi Yoshida-Komiya¹⁾ and Keiya Fujimori¹⁾

¹⁾Department of Obstetrics and Gynecology, Fukushima Medical University School of Medicine, Fukushima, Japan, ²⁾Fukushima Medical Center for Children and Women, Fukushima Medical University, Fukushima, Japan

(Received June 9, 2021, accepted February 16, 2022)

Abstract

Kallmann syndrome, a congenital disorder of idiopathic hypogonadotropic hypogonadism associated with anosmia, results in infertility because of anovulation. Assisted reproductive technology (ART) is considered when optimal ovulation induction therapy is difficult or when several cycles of ovulation induction therapy do not result in pregnancy. However, evidence is lacking regarding the optimal ART treatment for Kallmann syndrome. We report the case of a 33-year-old woman who successfully achieved pregnancy and delivery after ART treatment. At 29 years old, she was diagnosed with Kallmann syndrome due to hypothalamic amenorrhea and anosmia. At 33 years old, she revisited the hospital, desiring a child after one year of infertility. Due to anovulation, she was treated with gonadotropin therapy, but controlling follicular development was difficult, and thus ART treatment was initiated. The controlled ovarian stimulation (COS) protocol for ART treatment employed gonadotropins, recombinant follicular stimulating hormone/human menopausal gonadotropin plus human chorionic gonadotropin, to promote follicular growth. Four oocytes were retrieved, and two cleaved embryos were vitrified and cryopreserved. After vitrified-warmed embryo transfer of a morula stage embryo in a hormone replacement cycle, pregnancy was achieved but resulted in a miscarriage. A second oocyte retrieval was performed under the same COS; four oocytes were retrieved, and two cleaved embryos were vitrified and cryopreserved. Further, a pregnancy was achieved through the vitrified warmed embryo transfer. At 40 weeks and 6 days of gestation, a baby boy weighing 3,344 g with an Apgar score of 7/8 was delivered vaginally. The mother's postpartum course and neonate were free from adverse events. For women with Kallmann syndrome, ART treatment and selective embryo cryopreservation may be a reasonable and safe option.

Key words : Kallmann syndrome, gonadotropin therapy, assisted reproductive technology, frozen-thawed embryo transfer

Introduction

Kallmann syndrome is a congenital disorder of isolated gonadotropin-releasing hormone (GnRH)

deficiency, which is also referred to as idiopathic hypogonadotropic hypogonadism (IHH) and is associated with anosmia¹⁾. The etiology involves the failure of GnRH neuron migration to the hypothalamus dur-

Corresponding author : Toshifumi Takahashi E-mail : totakaha@fmu.ac.jp

©2022 The Fukushima Society of Medical Science. This article is licensed under a Creative Commons [Attribution-NonCommercial-ShareAlike 4.0 International] license.
<https://creativecommons.org/licenses/by-nc-sa/4.0/>

ing fetal stages²). Kallmann syndrome is a rare disorder, with a frequency of 1 in 8,000 in males and 1 in 40,000 in females^{3,4}.

Women with Kallmann syndrome lack secondary sexual characteristics, experience primary amenorrhea and infertility², and need ovulation induction to have children. Since the pathophysiology of Kallmann syndrome is due to insufficient GnRH secretion in the hypothalamus⁵⁻⁷, treatments such as GnRH pulse and gonadotropin therapy have been used for successful pregnancies⁸⁻¹³.

In Kallmann syndrome, as with other infertility cases, assisted reproductive technologies (ART), such as in vitro fertilization and embryo transfer (IVF-ET), are the treatments of choice when intercourse and artificial insemination with the husband's semen, in combination with ovulation induction therapy, do not result in pregnancy. To date, there have been few reports of pregnancies following ART treatment in patients with Kallmann syndrome¹⁴⁻¹⁶. Therefore, at present, there is a lack of evidence regarding the optimal ART treatment for these patients.

We report a case of an infertile woman with Kallmann syndrome and primary amenorrhea who underwent IVF and achieved pregnancy and delivery after vitrified-warmed ET. For comparison with this case, we also performed a literature review of reported cases of ART treatment for infertile women with Kallmann syndrome.

Case presentation

The patient was a 33-year-old Japanese nulligravida woman. Her medical history to date is as follows. At 16 years old, she visited a general gynecologist due to primary amenorrhea and a lack of secondary sexual characteristics. She received hormonal medication that resulted in uterine bleeding. Thereafter, she was administered cyclic estrogen and progesterone. At 29 years old, she was referred to our hospital, and hormonal examinations were conducted to determine the cause of her primary amenorrhea. Luteinizing hormone (LH) and follicle-stimulating hormone (FSH) levels were 0.5 mIU/ml (normal range, 1.76-10.24 mIU/ml in follicular phase of menstrual cycle) and 2.40 mIU/ml (normal range, 3.01-14.72 mIU/ml in follicular phase of menstrual cycle), respectively, and estradiol (E2) level was 5 pg/ml (normal range, 28.8-196.8 pg/ml in follicular phase of menstrual cycle). Hormonal examination revealed that she had hypogonadotropic hypogonadism. Thus, she underwent GnRH stimu-

lation tests. The results of the GnRH stimulation test are shown in Table 1. LH and FSH gonadotropin secretion was observed after GnRH administration, indicating that the hypogonadotropic hypogonadism was the result of a hypothalamic disorder. Furthermore, the patient had an inability to smell curry, and was diagnosed with anosmia by an otolaryngologist, following an odor test. In addition, magnetic resonance imaging (MRI) revealed an olfactory bulb defect. Based on these findings, the patient was diagnosed with Kallmann syndrome.

The patient married at 31 years old and was referred to our hospital at the age of 33, as she desired a child. The patient was 157 cm tall, weighed 58 kg, and had a body mass index of 23.5 kg/m². Her blood pressure was 112/71 mm Hg. Physical examination revealed no winged neck, cubitus valgus, or funnel breasts; moreover, her breast and pubic hair growth corresponded to Tanner stage 5. On internal examination, we discovered that the vulva was normal, and vaginoscopy showed vaginal erosion and a hen's egg-sized uterus; bilateral adnexa were not palpable. Transvaginal ultrasonography showed that the endometrium was 3.7 mm thick; however, the bilateral ovaries were difficult to detect. Routine blood and biochemical laboratory test results were normal. The hormonal profile test revealed the following results: LH 0.51 mIU/ml (normal range, 1.76-10.24 mIU/ml in follicular phase of menstrual cycle), FSH 1.55 mIU/ml (normal range, 3.01-14.72 mIU/ml in follicular phase of menstrual cycle), E2 16.5 pg/ml (normal range, 28.8-196.8 pg/ml in follicular phase of menstrual cycle), progesterone (P4) 0.07 ng/ml (normal range, <0.28 ng/ml in follicular phase of menstrual cycle), total testosterone 0.22 ng/ml (normal range, 0.11-0.47 ng/ml), anti-Müllerian hormone 1.34 ng/ml (normal range at 30-32 years, 0.64-14.2 ng/ml), thyroid-stimulating hormone 1.04 μ IU/ml (normal

Table 1. Hypothalamic-pituitary response to GnRH stimulation test at time of initial visit (29 years old)

Time after GnRH injection	LH (mIU/ml)	FSH (mIU/ml)
baseline	0.5	2.4
15 min	3.7	3.7
30 min	8.3	5.5
60 min	10.7	6.8
90 min	10.2	9.6
120 min	9.1	9.4

GnRH, gonadotropin-releasing hormone; LH, luteinizing hormone; FSH, follicle-stimulating hormone

range, 0.50–5.00 μ IU/ml), free triiodothyronine 3.64 pg/mL (normal range, 2.30–4.30 pg/ml), and free thyroxine 1.50 ng/dl (normal range, 0.90–1.70 ng/dl). Chromosome examination using G-banding revealed a normal karyotype of 46, XX. The patient declined to undergo genetic testing for Kallmann syndrome. Hysterosalpingography revealed a normal uterine cavity and a bilateral tubal passage. The husband’s semen analysis showed a volume of 1.9 mL, sperm concentration of 53×10^6 /ml, progressive motility of 30.6% (total motility of 38.9%), and 30% morphological normal spermatozoa. Asthenozoospermia was indicated by the semen findings, according to WHO criteria¹⁷.

Because Kallmann syndrome is due to insufficient GnRH secretion in the hypothalamus, typical treatment options are GnRH pulse or gonadotropin therapy. For this case, gonadotropin therapy was chosen, with recombinant FSH (rFSH, Gonal-F, Serono Japan, Tokyo, Japan) and human menopausal gonadotropin (hMG; ASUKA Pharmaceuticals, Tokyo, Japan) in combination. Moreover, an additional 5,000 units of human chorionic gonadotropin (hCG, gonadotropin, ASUKA Pharmaceuticals, Tokyo, Japan) were administered to promote follicle growth. Ovulation induction via gonadotropin therapy was performed for three cycles. However, due to poor follicle development that was difficult to control, the treatment was discontinued, and pregnancy was not achieved. Since it was difficult to control follicular

growth with gonadotropin therapy, ART treatment was proposed and patient consent obtained.

The controlled ovarian stimulation (COS) protocol for ART treatment employed gonadotropins (rFSH/hMG) plus hCG to promote follicular growth (Fig. 1). FSH levels were monitored to determine the amount of FSH required for follicular development for this case. In the first ART treatment cycle, ovarian stimulation was started on the third day of withdrawal bleeding (cycle day 3, CD 3); four mature follicles over 15 mm in diameter were observed on CD 18. Then on CD 21, 250 μ g of recombinant hCG (rhCG, Ovidrel, Merck Biopharma, Toyo, Japan) was subcutaneously administered, and the oocyte was retrieved 3 h later. Four cumulus-oocyte complexes (COCs) were harvested and subjected to IVF with the sperm from her partner. Three two-pronuclear embryos and one three-pronuclear embryo were observed one day after IVF. On day three, two embryos, one morula (G4 of Tao criteria¹⁸), and one seven-cell stage embryo with blastomeres of equal size and minor cytoplasmic fragmentation were cryopreserved by vitrification using CRYOTOP® (Kitazato, Shizuoka, Japan) according to the manufacturer’s protocol. No side effects, such as ovarian hyperstimulation syndrome (OHSS), were observed.

Vitrified-warmed ET was performed during a hormone replacement cycle. The endometrium was prepared as follows: the transdermal adminis-

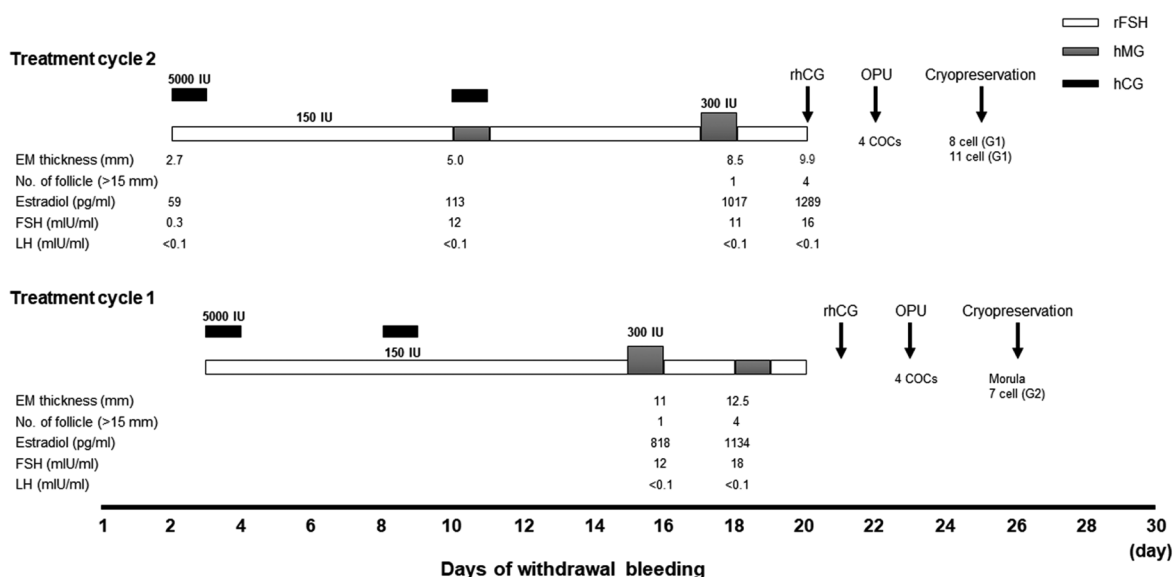


Fig. 1. Clinical course of assisted reproductive technology treatment cycles.

rFSH, recombinant follicle stimulating hormone; hMG, human menopausal gonadotropin; hCG, human chorionic gonadotropin; EM, endometrium; FSH, follicle stimulating hormone; LH, luteinizing hormone; IU, international unit; OPU, ovum pick up; COCs, cumulus-oocyte complexes

tration of E2 was started at 2.88 mg/day (Estrana TAPE ; Hisamitsu Pharmaceutical, Tokyo, Japan) every other day after the third day of withdrawal bleeding. Twelve days after E2 treatment, the endometrial thickness reached 10.5 mm ; vaginal P4 (LUTEUM ; Asuka Pharmaceutical, Tokyo, Japan, 400 mg twice daily) and oral chlormadinone acetate (Lutoral, Fuji Pharma, Tokyo, Japan, 6 mg daily) were administered. The morula-stage embryo was warmed using a thawing kit (VT602, Kitazato, Shizuoka, Japan), according to the manufacturer's protocol, and ET was performed on the fourth day after P4 administration. Transdermal E2 and P4 administration were continued until pregnancy was determined. Fourteen days after ET, a urine hCG test was positive. At 5 weeks and 3 days of gestation, transvaginal ultrasonography revealed one gestational sac in the uterus. At 7 weeks and 3 days of gestation, a fetal heartbeat was detected. At 9 weeks and 3 days of gestation, loss of the fetal heartbeat was confirmed, and the pregnancy was terminated by vacuum aspiration. After that, the remaining early cleavage embryo was warmed and transferred in the same way under a hormone replacement cycle, but no pregnancy occurred.

Therefore, the patient was scheduled for the second cycle of ART treatment. The same COS protocol was performed with gonadotropins (rFSH/hMG) and hCG to promote follicle growth (Fig. 1). The COS was commenced on CD 2 after withdrawal bleeding. The number of antral follicles at the time of COS initiation was two in both ova-

ries. On CD 20, transvaginal ultrasonography revealed an endometrium of 9.9 mm and four mature follicles over 15 mm in diameter. Subsequently, 250 µg of rhCG (Ovidrel, Merck Biopharma, Toyo, Japan) was administered by subcutaneous injection. On CD 22, oocyte retrieval was performed. Four COCs were retrieved, which were then subjected to IVF. Three days after IVF, one eight-cell stage embryo with blastomeres of equal size and no cytoplasmic fragmentation and one eleven-cell stage embryo with blastomeres of equal size and no cytoplasmic fragmentation were cryopreserved by vitrification. Vitrified-warmed ET was scheduled and performed during a hormone replacement cycle. The endometrium was prepared by transdermal administration of E2 at 3 mg/day (0.1% E2 gel, Divigel, Mochida Pharmaceutical, Tokyo, Japan) after three days of withdrawal bleeding. Then, the endometrial thickness reached 10.9 mm, and vaginal P4 (LUTEUM ; Asuka Pharmaceutical, Tokyo, Japan, 400 mg twice daily) and oral dydrogesterone (Duphaston, Mylan EPD, Tokyo, Japan, 15 mg daily) treatment was started. One eight-cell stage embryo was warmed using a thawing kit (VT602, Kitazato, Shizuoka, Japan) according to the manufacturer's protocol, and ET was performed on the fourth day after P4 administration. Transdermal E2 and P4 administration were continued until pregnancy was determined. Fourteen days after ET, a urine hCG test was positive. At 6 weeks of gestation, transvaginal ultrasonography revealed one gestational sac in the uterus. At 7 weeks of gestation,

Table 2. Case reports and retrospective cohort studies in Kallmann syndrome and hypogonadotropic hypogonadism

First author (Year)	Type of report (no. of cases)	Diagnosis	Age	Types of COS	Gonadotropin dose used (IU)	Duration of stimulation (days)
Szilagyi (2001)	Case report (1)	KS	20	GnRH agonist	2250-3150	NA
Ulug (2005)	Retrospective cohort (58)	HH	32*	hMG	HH (6071*) vs TI (3585*)	HH (13.61*) vs TI (11.69*)
Kumbak (2006)	Retrospective cohort (27)	HH	33*	GnRH antagonist	HH (4537*) vs UI (3178*)	HH (14.0*) vs UI (11.8*)
Yildirim (2010)	Retrospective cohort (10)	HH	31*	hMG	HH (3630*) vs TI (2501*)	HH (13.0*) vs TI (9.2*)
Caragia (2012)	Retrospective cohort (28)	HH	33*	NA	HH (4098*) vs TI (2694*)	HH (16.3*) vs TI (12.9*)
Ghaffari (2013)	Retrospective cohort (81)	HH	35*	hMG/FSH	HH (4845*) vs TI (2265*)	HH (13.8*) vs TI (10.4*)
Pandurangi (2015)	Case series (7)	HH	27*	hMG/FSH	NA	12-54
Yilmaz (2015)	Retrospective cohort (33)	HH	33*	hMG	HH (4741*) vs MI (2157*)	HH (12.5*) vs MI (10.8*)
Shimoda (2016)	Case report (1)	KS	30	hMG	4200	15
Mumusoglu (2017)	Retrospective cohort (57)	HH	31*	GnRH agonist or hMG/FSH	HH (3600**) vs control (2400**)	HH (11.6*) vs control (9.1*)
Kuroda (2018)	Retrospective cohort (79)	HH	33*	hMG	2292*	12.2*
Nishiyama (2019)	Case report (1)	KS	32	hMG	3600	13
Present case	Case report (1)	KS	33	hMG/FSH plus hCG	3150 (cycle 1) and 3150 (cycle 2)	18 (cycle 1) and 19 (cycle 2)

ART, assisted reproductive technology ; KS, Kallmann syndrome ; HH, hypogonadotropic hypogonadism ; COS, controlled stimulating hormone ; TI, tubal infertility ; UI, unexplained infertility ; MI, male infertility ; IVF, in vitro fertilization ; ICSI,

the fetal heartbeat was positive. Thereafter, her pregnancy course was free from adverse events. At 40 weeks and 6 days of gestation, a baby boy weighing 3,344 g with an Apgar score of 7/8 was delivered vaginally. The mother's postpartum course and neonate were free from adverse events.

Discussion

We report a case of an infertile woman with Kallmann syndrome presenting with primary amenorrhea. Although gonadotropin therapy did not result in pregnancy due to difficulty in regulating follicle growth, IVF followed by vitrified-warmed ET treatment resulted in successful conception and delivery.

GnRH pulse and gonadotropin therapy have been used for ovulation induction in patients with Kallmann syndrome⁵⁻⁷. GnRH pulse therapy mimics physiological GnRH secretion and has the advantage of being prone to monofollicular development, thus having a lower risk of multiple births and OHSS compared to gonadotropin therapy⁷. However, GnRH pulse therapy requires a special drug infusion pump and has the disadvantage of decreased patient convenience due to continuous subcutaneous injection; therefore, gonadotropin is often used in actual clinical settings.

Poor ovarian responsiveness to gonadotropin therapy ovulation induction has been reported in IHH patients, including those with Kallmann syndrome^{16,19}. IHH is a group of disorders that cause

idiopathic GnRH deficiency or GnRH hyposecretion. Kallmann syndrome is classified as a form of IHH and is associated with anosmia in IHH. Therefore, the ovarian response to gonadotropin therapy is expected to be the same in other IHH disorders besides Kallmann syndrome. It has been shown that follicular development proceeds in concert with steroid hormone production in the theca and granulosa cells that comprise the follicle²⁰. For instance, when LH secretion is very low, as in Kallmann syndrome and IHH, androgen production via LH in the theca cells of the follicle does not occur, resulting in decreased production of androstenedione and testosterone¹⁹. Androgens are used as substrates for aromatase to synthesize E2 in the granulosa cells of follicles. Therefore, where the effect of LH is reduced, follicular development may be inadequate when FSH preparations are administered alone.

Although hMG with LH activity is advantageous for follicular development in patients with IHH, it has been reported that rFSH alone can induce ovulation in patients with Kallmann syndrome and IHH^{9,21}. Moreover, it has been reported that administration of rFSH alone causes a poor increase in androstenedione but a remarkable increase in E2 levels and follicular development²². Since rFSH can be injected subcutaneously by oneself, it has the advantage of reducing the number of hospital visits. However, follicular growth is poor with rFSH alone, which is countered by combining it with hCG with LH activity and hMG.

women with primary amenorrhea who underwent ART treatments

No. of retrieved oocytes	Type of insemination	Fresh or frozen-thawed ET	No. of ET	Live birth or clinical pregnancy/ET	Adverse events
4 and 6	ICSI	Fresh	2 and 4	Live birth	None
12.4*	IVF	Fresh	3.0*	30/53 (56.6%)	Multiple pregnancies (46.6%)
10.3*	IVF/ICSI	Fresh	3.5*	16/27 (59.3%)	NA
6.5*	ICSI	Fresh	2.6*	8/10 (80%)	None
9.1*	IVF/ICSI	Fresh	NA	56.6%	NA
8.3*	IVF/ICSI	Fresh	2.2*	14/72 (19.4%)	NA
9.9*	ICSI	Fresh : 5 cycles Frozen : 3 cycles (cleaved embryos)	2.4*	6/8 (75%)	NA
10.0*	IVF/ICSI	Fresh	NA	10/33 (33%)	NA
2.0	ICSI	Frozen (cleaved embryos)	1.0	Live birth	None
8.0*	ICSI	Fresh (cleaved embryo or blastocyst)	1.0*	21/57 (36.8%)	None
9.9*	IVF/ICSI	Frozen (cleaved embryo or blastocyst)	1.0*	80/135 (59.3%)	None
13	IVF/ICSI	Frozen (blastocyst)	1.0	Ongoing	None
4 (cycle 1) and 4 (cycle 2)	IVF	Frozen (cleaved embryos)	1.0	Ongoing	None

ovarian stimulation; GnRH, gonadotropin-releasing hormone; hMG, human menopausal gonadotropin; FSH, follicle-intracytoplasmic sperm injection; ET, embryo transfer; NA, not available, *mean value, **median value

ART is considered the next treatment option when pregnancy cannot be achieved with gonadotropin therapy or when optimal follicular growth cannot be controlled. Table 2 summarizes the reports on ART treatment for patients with IHH, including those with Kallmann syndrome^{14-16,23-31}. Among these, only three reported ART treatments exclusively for patients with Kallmann syndrome¹⁴⁻¹⁶. One was a fresh ET treatment cycle after ICSI¹⁴, while the other two cases involved a frozen-thawed ET treatment cycle after IVF or ICSI^{15,16}. The remaining nine reports included IHH and secondary HH. Summarizing these, the median clinical pregnancy or live birth rate after ART treatment for HH was 57.95% (range 19.4%-80%). Moreover, eight were fresh, and two were frozen-thawed ET cycles, and one was a combination of both. Recently, Kuroda *et al.* reported that a combination of freeze-all embryo and single vitrified-warmed ET with a hormone replacement cycle for HH, including IHH, had good cumulative pregnancy rates of 73.4% in up to 3 ET cycles³⁰. Seven retrospective cohort studies comparing IHH with tubal or male infertility and other causes of poor ovarian responsiveness to gonadotropins have been reported^{23-27,29,31}. In these reports, the total amount of gonadotropin used and the duration of ovarian stimulation were significantly higher in IHH than in other causes of infertility. These studies suggest that ovarian responsiveness to gonadotropins is poorer in IHH.

Gao *et al.* reported a systematic review and meta-analysis of ART treatment for IHH in women³². In the report, miscarriage, multiple pregnancy, OHSS, and ectopic pregnancy were reported as side effects of ART treatment. Although patient age and other factors were not considered, they reported that the miscarriage rate and multiple pregnancy rate after ART treatment for IHH were 8.2% and 12.8%, respectively, and were not significantly different from other patients treated with ART. Taken together, these reports suggest that ART is an acceptable treatment for IHH disorders such as Kallmann syndrome, in terms of the outcomes and side effects.

In this report, we have described the treatment of an infertile woman with Kallmann syndrome who underwent IVF under COS with rFSH/hMG plus hCG, which resulted in successful pregnancy and delivery after vitrified-warmed ET. Although there are only a few reports of ART treatments being performed for patients with Kallmann syndrome, IVF followed by selective embryo cryopreservation seems to be a safe and effective ART treatment for

patients with Kallmann syndrome.

Conflict of interest

The authors declare no conflict of interest.

References

1. Bry-Gauillard H, Trabado S, Bouligand J, *et al.* Congenital hypogonadotropic hypogonadism in females: clinical spectrum, evaluation and genetics. *Ann Endocrinol (Paris)*, **71**: 158-162, 2010.
2. Cadman SM, Kim SH, Hu Y, Gonzalez-Martinez D, Bouloux PM. Molecular pathogenesis of Kallmann's syndrome. *Horm Res*, **67**: 231-242, 2007.
3. Young J, Xu C, Papadakis GE, *et al.* Clinical Management of Congenital Hypogonadotropic Hypogonadism. *Endocr Rev*, **40**: 669-710, 2019.
4. Dode C, Hardelin JP. Kallmann syndrome. *Eur J Hum Genet*, **17**: 139-146, 2009.
5. Christou F, Pitteloud N, Gomez F. The induction of ovulation by pulsatile administration of GnRH: an appropriate method in hypothalamic amenorrhea. *Gynecol Endocrinol*, **33**: 598-601, 2017.
6. Battaglia C, Salvatori M, Regnani G, Giulini S, Primavera MR, Volpe A. Successful induction of ovulation using highly purified follicle-stimulating hormone in a woman with Kallmann's syndrome. *Fertil Steril*, **73**: 284-286, 2000.
7. Martin KA, Hall JE, Adams JM, Crowley WF, Jr. Comparison of exogenous gonadotropins and pulsatile gonadotropin-releasing hormone for induction of ovulation in hypogonadotropic amenorrhea. *J Clin Endocrinol Metab*, **77**: 125-129, 1993.
8. Nakagawa K, Iwasaki W, Sato M, *et al.* Successful pregnancy, achieved by ovulation induction using a human menopausal gonadotropin low-dose step-up protocol in an infertile patient with Kallmann's syndrome. *J Obstet Gynaecol Res*, **31**: 140-143, 2005.
9. Kousta E, White DM, Piazzzi A, Loumaye E, Franks S. Successful induction ovulation and completed pregnancy using recombinant human luteinizing hormone and follicle stimulating hormone in a woman with Kallmann's syndrome. *Hum Reprod*, **11**: 70-71, 1996.
10. Sungurtekin U, Fraser IS, Shearman RP. Pregnancy in women with Kallmann's syndrome. *Fertil Steril*, **63**: 494-499, 1995.
11. Aharoni A, Tal J, Paltieli Y, Porat N, Leibowitz Z, Sharf M. Kallmann syndrome: a case of twin pregnancy and review of the literature. *Obstet Gynecol Surv*, **44**: 491-494, 1989.
12. Chryssikopoulos A, Gregoriou O, Papadias C,

- Loghis C. Gonadotropin ovulation induction and pregnancies in women with Kallmann's syndrome. *Gynecol Endocrinol*, **12** : 103-108, 1998.
13. Yu HT, Lee CL, Huang HY, Soong YK. Successful pregnancy in a woman with Kallmann's syndrome using human menopausal gonadotropin followed by low-dose human chorionic gonadotropin in the mid-to-late follicular phase. *Taiwan J Obstet Gynecol*, **51** : 300-302, 2012.
 14. Szilagyi A, Manfai Z, Kiesel L, Szabo I. Kallmann's syndrome : pregnancy through intracytoplasmic sperm injection and complicated by gestational diabetes. *Gynecol Endocrinol*, **15** : 325-327, 2001.
 15. Shimoda M, Iwayama H, Ishiyama M, Nakatani A, Yamashita M. Successful pregnancy by vitrified-warmed embryo transfer for a woman with Kallmann syndrome. *Reprod Med Biol*, **15** : 45-49, 2016.
 16. Nishiyama R, Kitaya K, Takaya Y, *et al*. Successful ongoing pregnancy following cryopreserved-thawed blastocyst transfer in an infertile Kallmann syndrome woman with balanced reciprocal translocation : a case report. *Clin Exp Obstet Gynecol*, **46** : 331-332, 2019.
 17. Organization WH. WHO laboratory manual for the examination and processing of human semen. Geneva, Switzerland, 2010.
 18. Tao J, Tamis R, Fink K, Williams B, Nelson-White T, Craig R. The neglected morula/compact stage embryo transfer. *Hum Reprod*, **17** : 1513-1518, 2002.
 19. Schoot DC, Harlin J, Shoham Z, *et al*. Recombinant human follicle-stimulating hormone and ovarian response in gonadotrophin-deficient women. *Hum Reprod*, **9** : 1237-1242, 1994.
 20. Raju GA, Chavan R, Deenadayal M, *et al*. Luteinizing hormone and follicle stimulating hormone synergy : A review of role in controlled ovarian hyper-stimulation. *J Hum Reprod Sci*, **6** : 227-234, 2013.
 21. Shoham Z, Mannaerts B, Insler V, Coelingh-Bennink H. Induction of follicular growth using recombinant human follicle-stimulating hormone in two volunteer women with hypogonadotropic hypogonadism**Supported by Organon International, Oss, The Netherlands. *Fertil Steril*, **59** : 738-742, 1993.
 22. Ben-Chetrit A, Gotlieb L, Wong PY, Casper RF. Ovarian response to recombinant human follicle-stimulating hormone in luteinizing hormone-depleted women : examination of the two cell, two gonadotropin theory. *Fertil Steril*, **65** : 711-717, 1996.
 23. Ulug U, Ben-Shlomo I, Tosun S, Erden HF, Akman MA, Bahceci M. The reproductive performance of women with hypogonadotropic hypogonadism in an in vitro fertilization and embryo transfer program. *J Assist Reprod Genet*, **22** : 167-171, 2005.
 24. Kumbak B, Kahraman S. Women with hypogonadotropic hypogonadism : cycle characteristics and results of assisted reproductive techniques. *Acta Obstet Gynecol Scand*, **85** : 1453-1457, 2006.
 25. doYildirim G, Ficicioglu C, Attar R, Akcin O, Tecelioglu N. Comparison of reproductive outcome of the women with hypogonadotropic hypogonadism and tubal factor infertility. *Clin Exp Obstet Gynecol*, **37** : 120-122, 2010.
 26. Caragia A, Vlismas A, Pepas L, Mohamed M, Tozer A, Sabatini L. ART and pregnancy outcome in hypogonadotrophic hypogonadism patients compared to matched controls. *Fertil Steril*, **98** : S286, 2012.
 27. Ghaffari F, Arabipoor A, Lankarani NB, Etminan Z, Tehraninejad ES. Assisted reproductive technique outcomes in hypogonadotropic hypogonadism women. *Ann Saudi Med*, **33** : 235-240, 2013.
 28. Pandurangi M, Tamizharasi M, Reddy NS. Pregnancy outcome of assisted reproductive technology cycle in patients with hypogonadotropic hypogonadism. *J Hum Reprod Sci*, **8** : 146-150, 2015.
 29. Mumusoglu S, Ata B, Turan V, *et al*. Does pituitary suppression affect live birth rate in women with congenital hypogonadotrophic hypogonadism undergoing intra-cytoplasmic sperm injection? A multicenter cohort study. *Gynecol Endocrinol*, **33** : 728-732, 2017.
 30. Kuroda K, Ezoe K, Kato K, *et al*. Infertility treatment strategy involving combined freeze-all embryos and single vitrified-warmed embryo transfer during hormonal replacement cycle for in vitro fertilization of women with hypogonadotropic hypogonadism. *J Obstet Gynaecol Res*, **44** : 922-928, 2018.
 31. Yilmaz S, Ozgu-Erdinc AS, Yumusak O, Kahyaoglu S, Seckin B, Yilmaz N. The reproductive outcome of women with hypogonadotropic hypogonadism undergoing in vitro fertilization. *Syst Biol Reprod Med*, **61** : 228-232, 2015.
 32. Gao Y, Yu B, Mao J, Wang X, Nie M, Wu X. Assisted reproductive techniques with congenital hypogonadotropic hypogonadism patients : a systematic review and meta-analysis. *BMC Endocr Disord*, **18** : 85, 2018.